

Chapter 9

Establishing Intravenous Access

If possible, concurrent with the initiation of external cooling, begin administration of transport medications. Introduction of stabilizing medications in adequate concentrations with sufficient rapidity can only be achieved via direct introduction into the circulatory system. An obvious prerequisite for such administration is vascular access.

Medications should never be administered through an artery. Arteries carry blood away from the heart and deliver it to the tissues. Administration of medication via an artery will frequently result in tissue death and sloughing of the area supplied by that artery. Medications are always administered through the low-pressure venous circulation, where they are carried back to the heart and rapidly diluted in the central circulation, and then evenly distributed to all the tissues.

Intravenous (IV) cannulation is a means to gain direct access to the venous circulation, either peripheral or central. There are two reasons for obtaining venous access in suspension patients:

- 1) To administer stabilizing or supportive fluids and drugs.
- 2) To obtain specimens of venous blood for later laboratory evaluation.

A routine part of transport and stabilization is the gaining of direct access to the venous circulation as early as possible, in order to establish an IV lifeline to administer essential drugs and assure their immediate uptake and distribution.

Many drugs used in transport could be administered via intramuscular or subcutaneous routes. However, absorption of the drug into the capillary blood perfusing the tissues is dependent upon blood flow. In low cardiac output states, such as those present during clinical death, blood is shunted away from skin and muscle. This markedly impairs uptake and distribution of the drug. If the drug is administered IV, access to the circulation is assured.

The discussion which follows will address both percutaneous (through the skin) IV techniques and cutdown procedures where the vein is accessed and opened surgically for catheter insertion:

Peripheral vein puncture:

- a) arm vein
- b) leg vein
- c) femoral vein

Cutdown Procedure:

- a) antecubital vein
- b) saphenous vein

After a brief description of various needles and cannulas, and a discussion of the general principles of IV therapy, the specific anatomy, indications, performance criteria, and complications for each technique will be detailed.

Intravenous Cannulas

There are essentially three types of IV cannulas which are likely to be used in transport operations: (1) hollow needles (including those attached to a syringe, and the type attached to a short length of plastic tubing with stabilizing "butterfly" wings); (2) indwelling plastic catheters inserted *over* a hollow needle; and (3) indwelling plastic catheters inserted either *through* a hollow needle or over a guide wire which is previously introduced through a needle.

NEEDLES AND CATHETERS FOR PERIPHERAL LINES

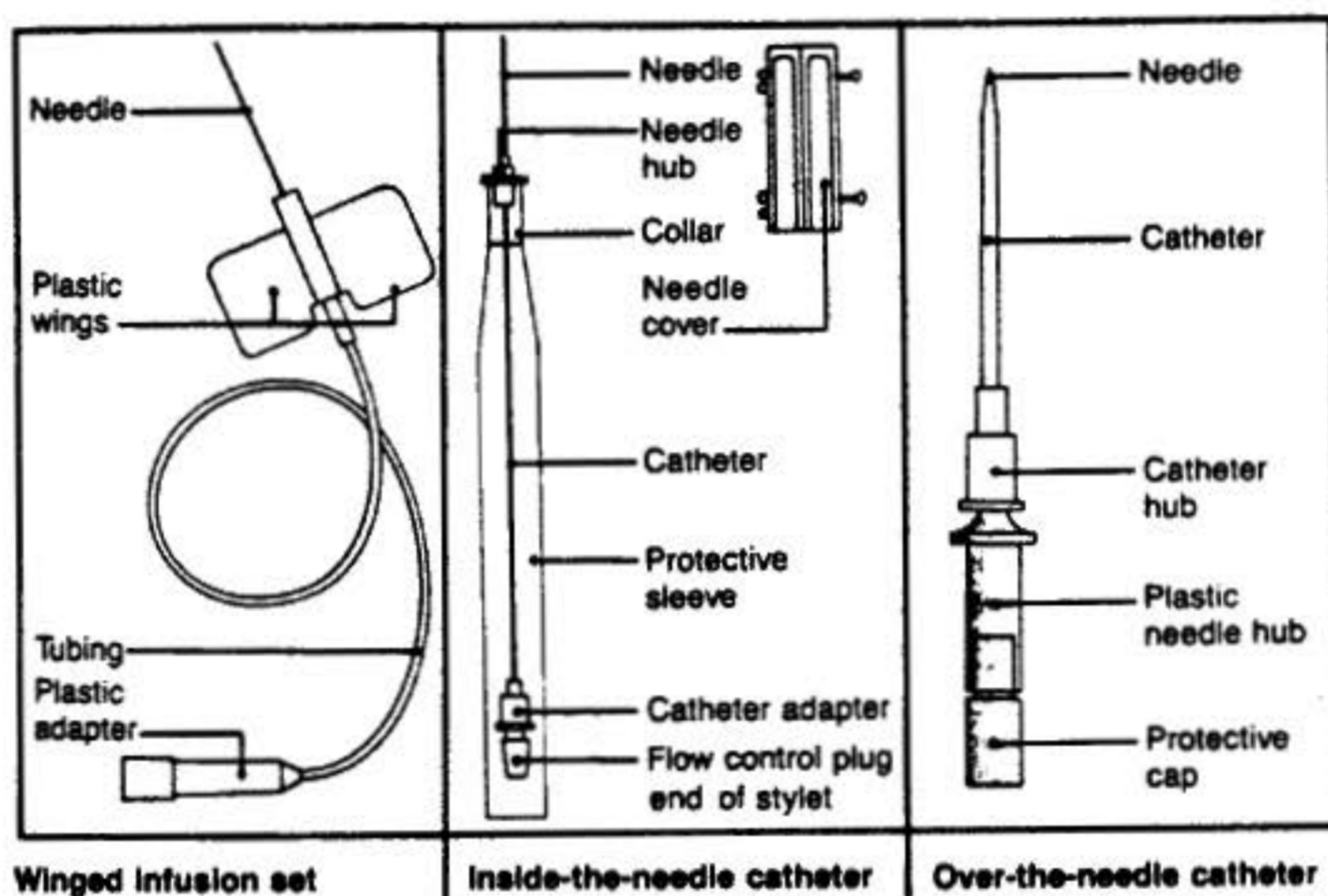


Figure 9-1: Three kinds of IV catheters commonly in use.

Where possible, plastic catheters rather than hollow needles should be used for transport IV therapy, since they can better be anchored and present less chance of infiltrating or puncturing the wall of the vessel in which they are placed.

Due to the relatively large volume of solution to be administered during transport, as well as the high viscosity of the Dextran-40, it is wise to use the largest gauge catheter possible. The flow rate through a 14-gauge catheter of 5 cm length averages 125 ml/min; through a 16-gauge catheter, 50 ml/min; through an 18-gauge catheter, 20 ml/min; and through a 20-gauge catheter, 8 ml/min.

Selection of catheter length depends upon the site of insertion. For cannulation of a peripheral vein, a needle and catheter length of 5 cm. is adequate.

If the patient has experienced legal death in a hospital setting, there may be a catheter(s) and IV line(s) in place. Insuring that existing IV's and other sources of circulatory access (Hickman catheter, arterial line, AV shunt, and so on) are not removed at or after pronouncement of legal death is an essential part of negotiation with hospital

personnel. In such instances where an existing IV is present, transport medications may be substituted for or "piggybacked" onto the saline or other "keep open" medication that prevents the catheter from clotting off. In such instances, it will be important to establish that the proper type of IV set is in place for the medication which needs to be administered (i.e., vented or unvented IV set).

In most instances where the transport technician is responsible for inserting the catheter and establishing the IV, a catheter-over-needle device will be preferred. The vein puncture is made with the device and the catheter is advanced into the vessel before the needle is removed. The male connector on the end of the IV tubing is then directly connected to the end of the plastic catheter, which is fitted with a standard female "luer" connector.

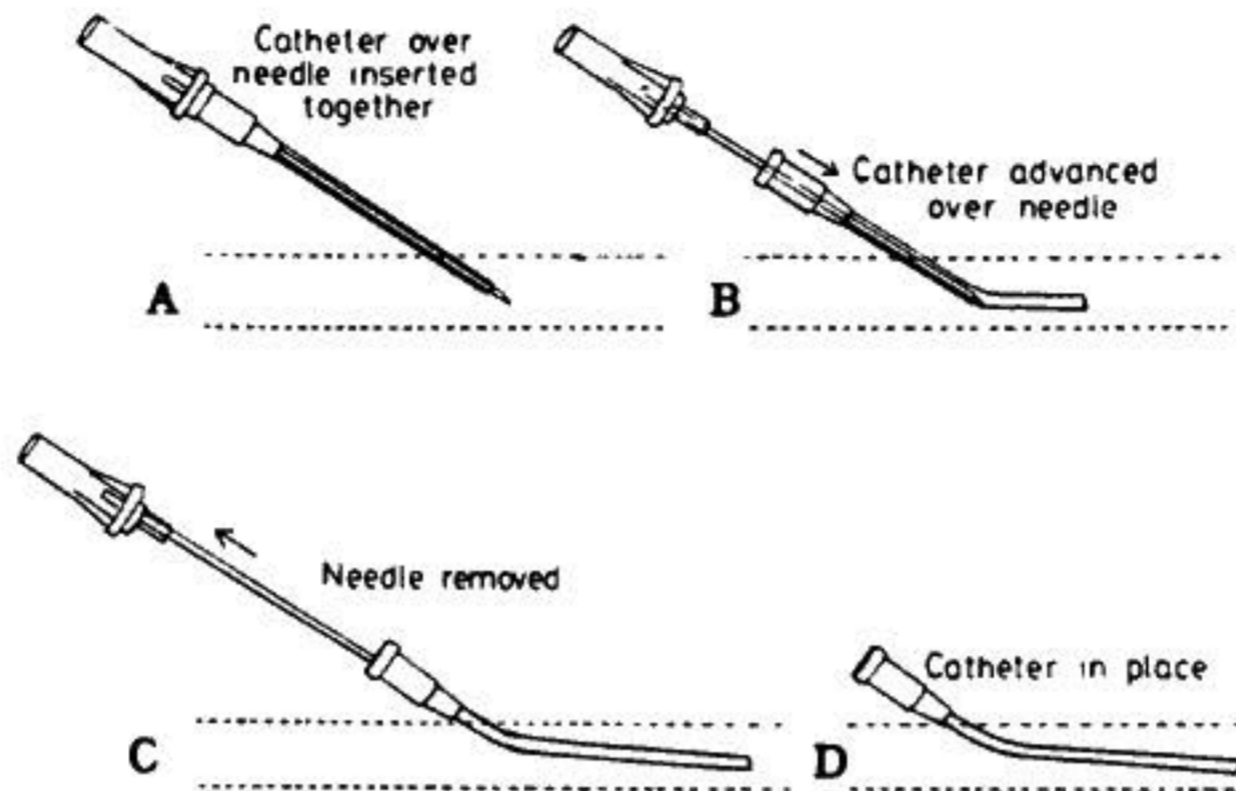


Figure 9-2: Insertion of catheter over needle.

General Principles Of IV Therapy

During cardiopulmonary resuscitation, cannulation of peripheral veins will be necessary to avoid interrupting CPR. After the catheter is inserted, attach sterile infusion tubing of the unvented type, with injection sites near the tip of the tubing, and then begin the administration of mannitol. Other medications can then be given through the rubber medication port by direct injection with a syringe and needle or by piggybacking additional IV sets (where large volumes of solution are to be given) by placing a needle on another IV set for administration through the injection site.

Hazards Of IV Therapy

The only three complications of concern in IV therapy in the transport of suspension patients are hematoma formation, infiltration, and air embolism. A hematoma occurs when blood leaks from a puncture site in a vessel and accumulates under the skin, forming a blood-filled pocket or cavity. Since the pressure inside this blood-filled cavity will quickly equal the venous pressure, the accumulated blood effectively closes off the vessel at the point of the hematoma. Infusion of solution will be brought to a halt and the vessel can be re-entered only at a point more proximal to the heart than to the hematoma. Hematomas are usually the result of poor technique in entering the vessel or anchoring the catheter. They are more likely to occur with inexperienced personnel or in the elderly or others with friable vessels or so-called "poor veins".




Figure 9-3: *Incorrect technique in introducing the catheter into the vessel can result in puncture of the posterior wall of the vessel.*

An infiltration is much the same as a hematoma, but with greater potential for harm, since the source of the high pressure, fluid-filled pocket is the solution being administered, rather than the patient's blood. Many of the solutions and medications employed during transport are highly concentrated (hyperosmotic) or are direct tissue irritants. Unlike blood, colloid or crystalloid IV solutions will not clot, and they are delivered under pressures of 30 to 50 mmHg (normal venous blood pressure is 2 to 3 mmHg). An infiltration of such medications, unless promptly detected, can cause massive fluid distention of the extremity and result in serious tissue damage.

Both hematomas and infiltrations can be avoided, and their effects minimized if they do occur, by careful attention to good technique and by periodically rechecking the site of the IV for signs of swelling, fluid accumulation, or discoloration. In the event that an infiltration or hematoma is suspected, stop solution administration immediately, prep a new site, and insert another IV.

Air embolism (introduction of air into the circulatory system) should not occur for any reason. It is an unacceptable and inexcusable complication which results only from negligence in the administration of IV fluids. Air embolism causes serious blockage of the circulatory system (in the lungs), and is a disaster. It interrupts and prevents adequate resuscitation and stabilization, and it is potentially disrupting to the distribution of cryoprotective agents during subsequent total body washout (TBW) and perfusion.

Air embolism can evolve in four ways:

(1) Through administration of an infusion of IV solution under pressure with air in the system. An example of this would be the use of a pressurized bag or bottle which contains some air at the top. If the technician allows the solution to be exhausted, air under pressure will then flow down the infusion set and into the patient's circulation. Pressure infusion (either the bag type or syringe pumping of the vent port on a glass bottle) should only be done with constant supervision of the liquid level in the container and with a hand in constant contact with the occluding clamp on the infusion set. Pressure infusion of any solution should be used judiciously for this reason.

(2) Through the venturi effect. If a needle from a second, vented container is inserted into the flow line of an existing IV (i.e., piggybacked), and the second container runs dry, air may be drawn into the system by the fluid flowing around the needle tip. Vented containers piggy-backed in this way must be carefully monitored, as above, to prevent introduction of air by the venturi effect.

(3) Through administration of trapped air. If the bottle is changed after it has been allowed to run dry, air has entered the solution administration tubing. The air trapped in the tubing may be forced into the patient by the pressure of the fresh solution. Always completely occlude (clamp) the line when changing bottles. Prior to restarting an infusion, always check the entire length of the administration set tubing and drip chamber to insure that no air is present and that there is an adequate level of fluid in the drip chamber to prevent introduction of bubbles as a result of turbulence during high flow rate fluid administration.

(4) Through negative or very low venous pressure such as with a central venous catheter. In many instances, transport medications will be administered through an existing IV, very often a "Hickman" or other type of central venous catheter. The pressure in the central venous system (CVP) is normally very low (significantly below that of the peripheral venous pressure), and tilting of the patient during transport or manipulation of the chest during CPR may cause a transiently negative CVP, resulting in air being drawn into the patient's circulation if an IV has been allowed to run dry. The basic rule: *Never let an IV run dry!*

Selection Of Peripheral Veins

Veins of the antecubital fossa (inner aspect of the elbow) are the first choice. These veins are easy to access, very superficial, fairly large, and well supported by muscular and connective tissue--hence unlikely to "roll" (slide or move under the skin). The most commonly used vein is the median cephalic, although any other in the area is satisfactory.

Veins on the back of the hand and on the ankle may also have to be used, particularly if the patient has had extensive previous IV cannulation or has been given sclerosing (vein obliterating) medication such as chemotherapeutic agents. Such veins are difficult to enter and "roll" easily.

The selection of the vein may be a deciding factor in achieving a successful outcome of catheter placement and fluid infusion. The most prominent vein is not necessarily the most suitable for venipuncture: prominence may be due to sclerosis of the vessel, which occludes the lumen and interferes with the flow of solution; or the prominent vein may be located in an area impractical for infusion purposes.

Palpation (feeling) of the vein is an important step in determining its condition and in differentiating it from a pulsating artery. A thrombosed vein may be detected by its lack of resiliency, by its hard, cordlike feeling, and by the ease with which it rolls. Use of such traumatized veins will only result in hematoma formation, infiltrations, and repeated vein punctures.

Edema may sometimes conceal an available vein; a few seconds of pressure with the fingers often helps to disperse the fluids and define the vein.

ANATOMY OF THE EXTREMITIES

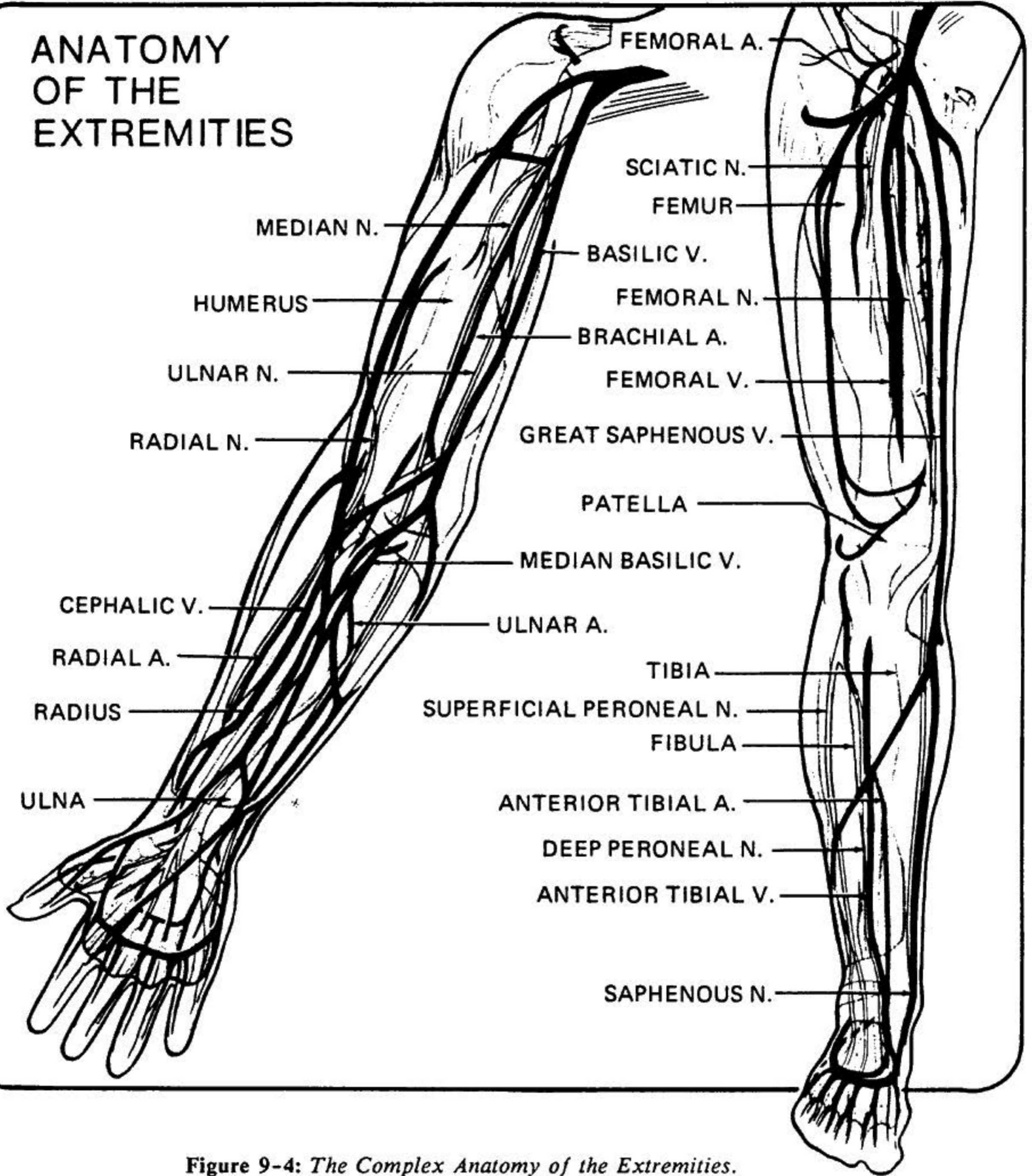


Figure 9-4: The Complex Anatomy of the Extremities.

Anatomy: Upper Extremities

On the dorsum (back) of the hand, a series of veins arise from the *digital veins*, which run parallel to the long axis of the hand, interconnected by a series of arches which form the *dorsal plexus*. At the radial side of the dorsal plexus, a thick vein, the *superficial radial vein*, runs laterally up the antecubital fossa and joins the *medial cephalic vein* to form the cephalic vein. Other superficial veins on the ulnar aspect of

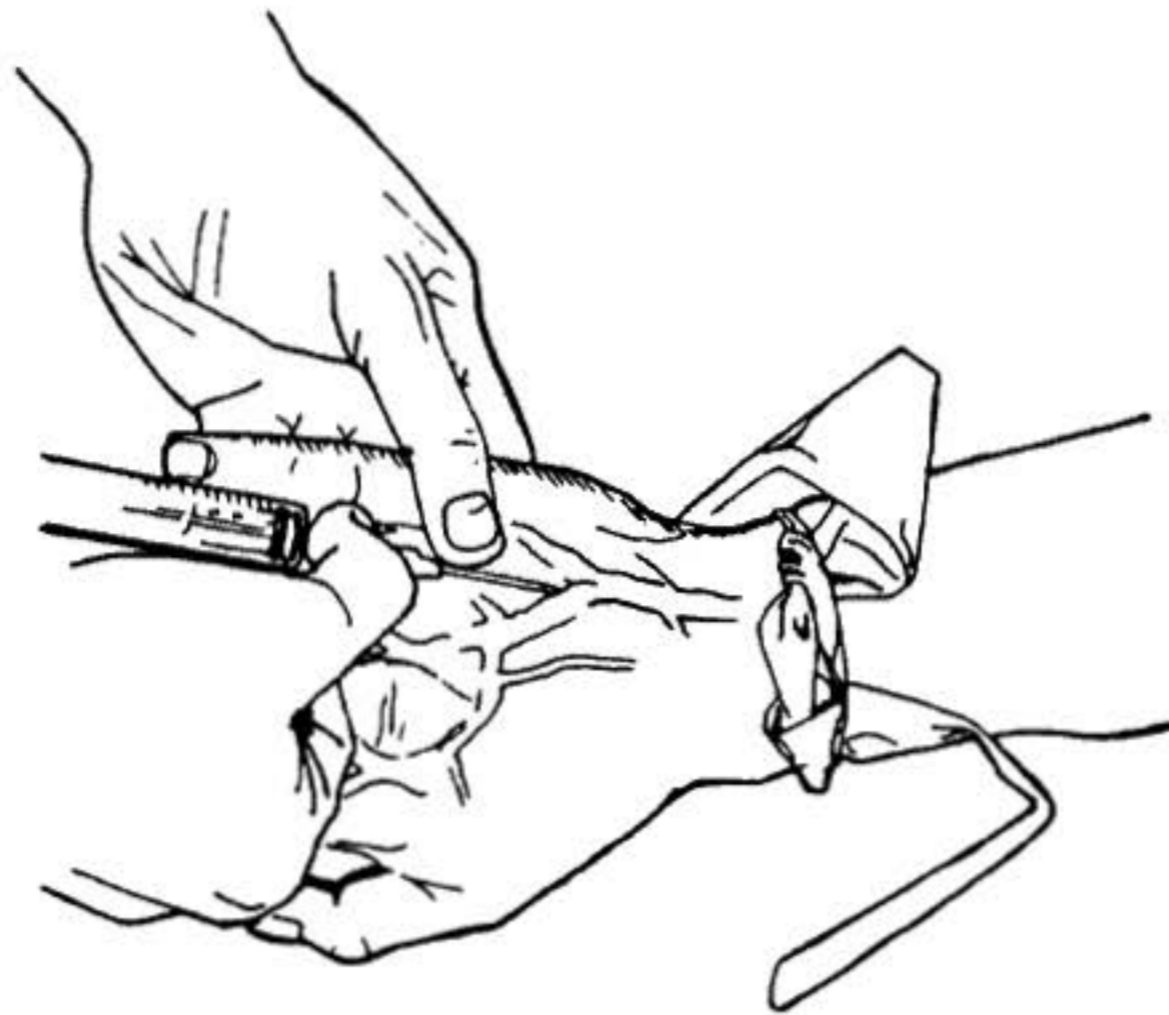


Figure 9-5: *Venipuncture Of Dorsal Hand Vein.*

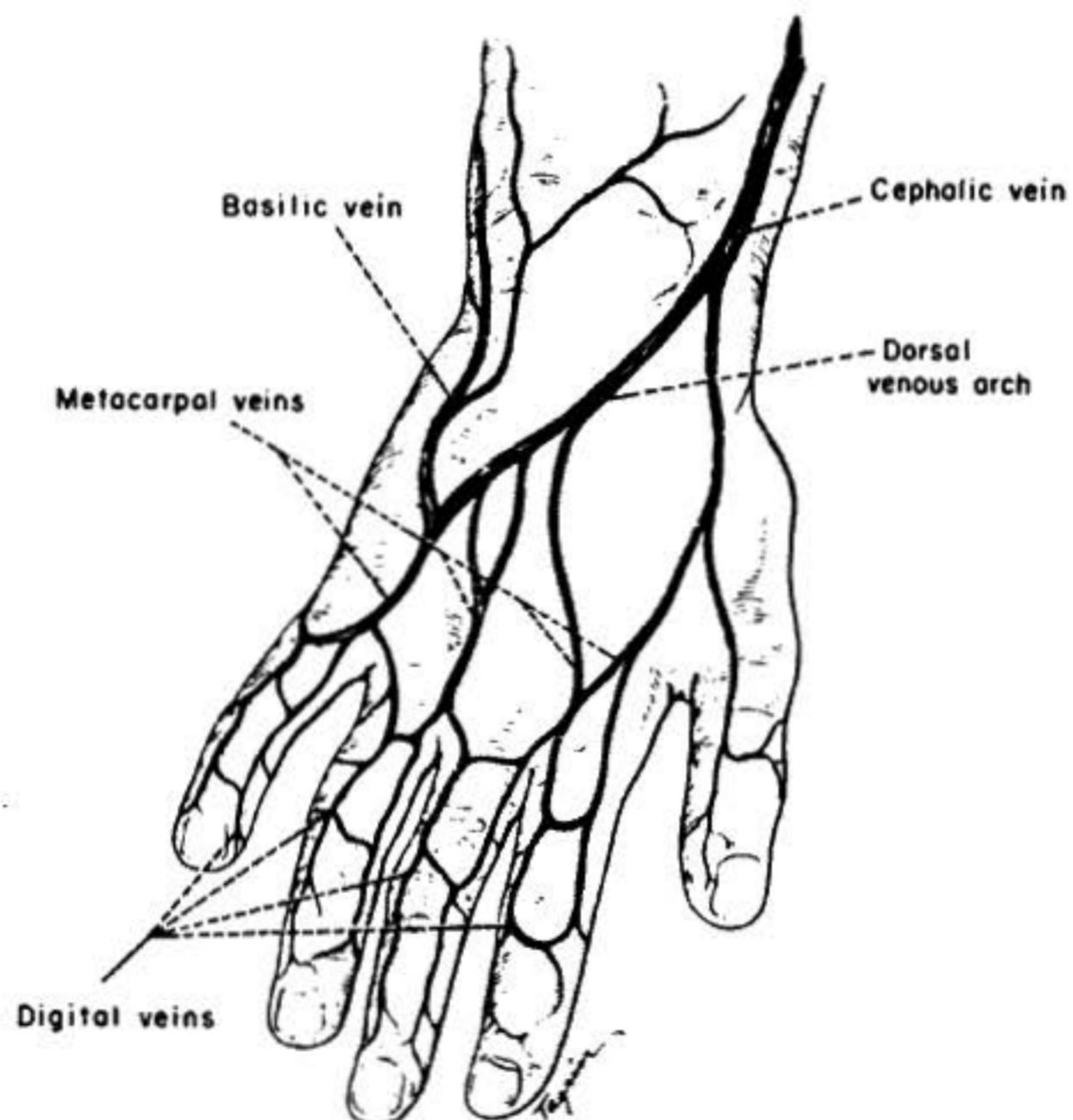


Figure 9-6: *Superficial veins of the hand.*

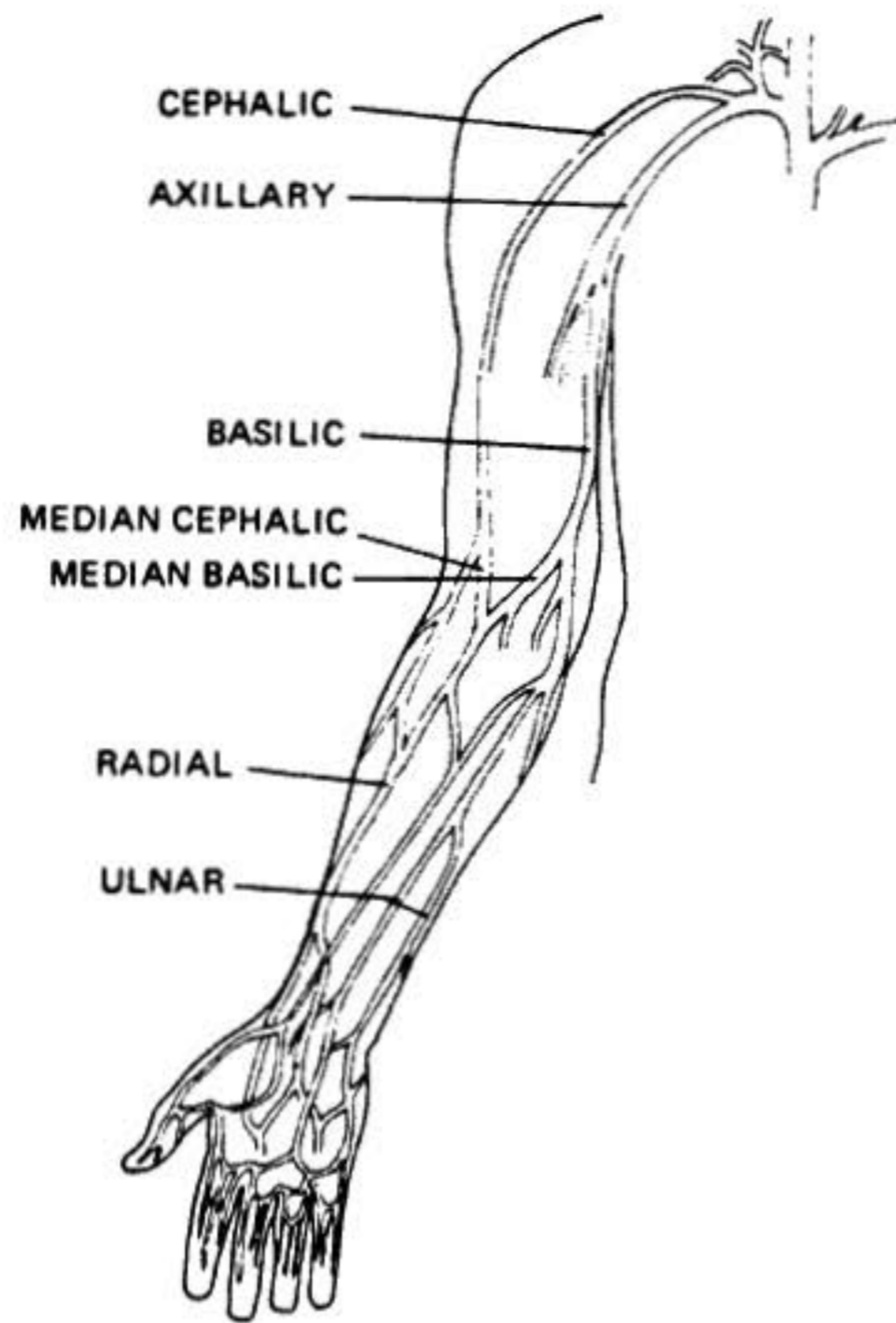


Figure 9-7: *Superficial veins of the forearm.*

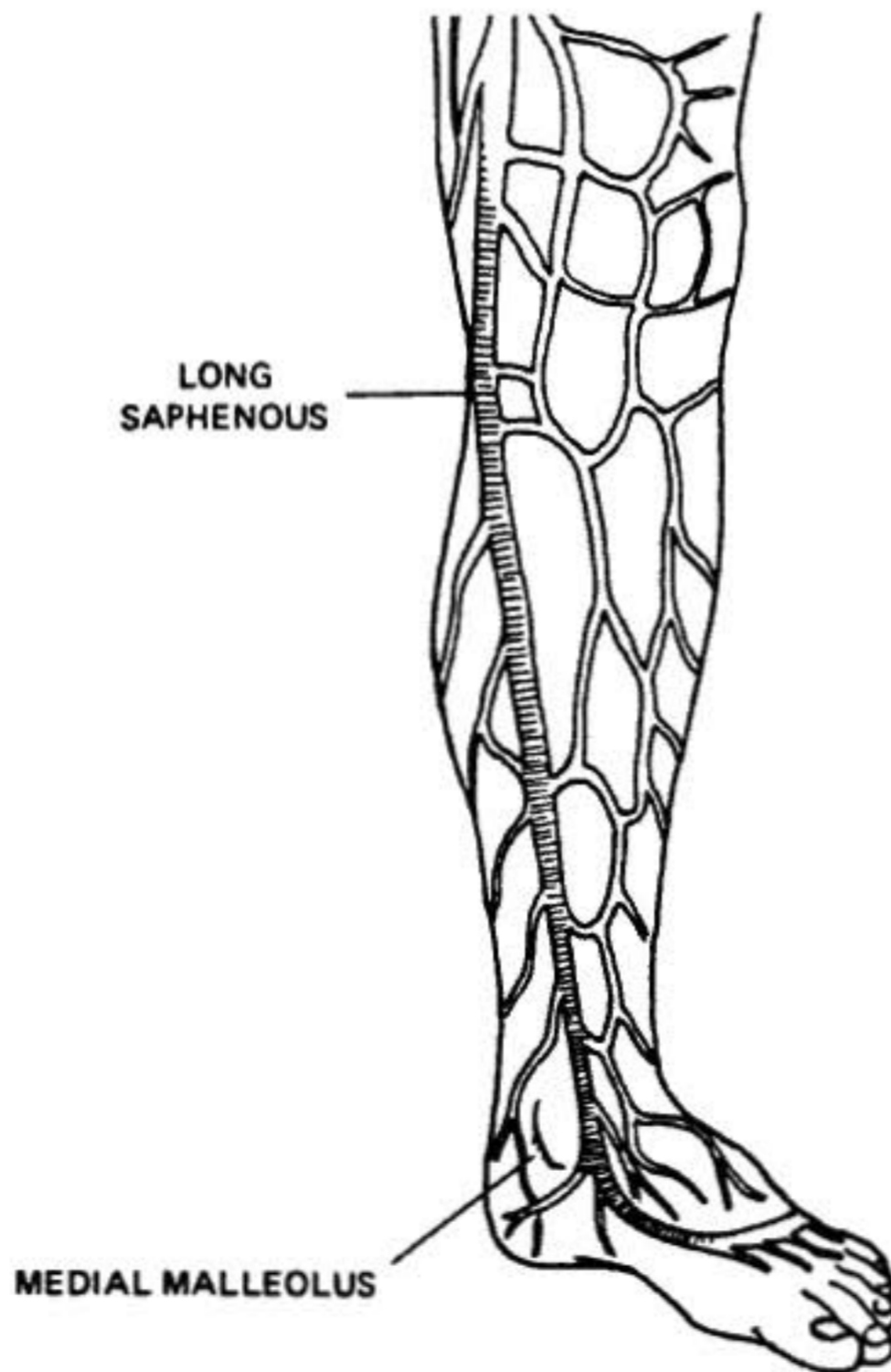


Figure 9-8: *Superficial veins of the leg.*

the forearm run to the elbow and join the *median basilic vein* to form the *basilic vein*. The median vein of the forearm bifurcates into a "Y" in the antecubital fossa, laterally becoming the *median cephalic* and medially becoming the medial basilic.

The basilic vein passes up the inner side of the arm, becoming deep at the lower third of the arm. As it continues cephalically, it joins the *brachial vein* to become the *axillary vein*. The cephalic vein continues laterally up the arm, crosses anteriorly, and becomes deep in the interval between the pectoralis major and the deltoid muscles; after a sharp angulation, it joins the axillary vein at a 90° angle, an anatomic detail which makes the cephalic vein unsuitable for insertion of pulmonary artery or central venous catheters.

Anatomy: Lower Extremities

The long *saphenous vein* begins on the inner side of the foot, receiving branches from the dorsal venous arch of the foot. It travels upward in front of the medial malleolus of the tibia to the groove between the upper medial end of the tibia and the calf muscle, and passes backward behind the internal condyle of the femur. It then runs somewhat outward and upward on the inner side of the front of the thigh to about 1½ in. below the inguinal ligament, where it pierces the saphenous opening to end in the *femoral vein*.

Technique: Peripheral Venipuncture

Preparation For Venipuncture

Assemble the equipment required for the operation. This should include a Velcro-type tourniquet, cleansing swabs (povidone-iodine (Betadine) or alcohol), a needle-catheter assembly of the appropriate gauge, sterile gauze, and plastic or cloth tape for securing the catheter or the IV line to the patient's limb.

All solutions required to begin IV therapy should be prepared and ready for use so that IV support can begin as soon as venipuncture is complete.

The solution to be administered should be carefully examined for any change in appearance or for the presence of particulate matter.

Checking For Damage

Before opening or spiking a container of IV solution, be certain to check the glass (if it is a glass container) for hairline fractures or cracks. Holding it up to a strong light and slowly rotating the bottle while carefully visually inspecting it will reveal the cracks. Because these medications will have been transported, often by air or over considerable distance, insuring that the glass is intact is of great importance. Always be sure that a vacuum is present when solutions in glass containers are first opened, or "spiked," with the solution administration set. If the bottles are spiked in the inverted position, the large bubbles will indicate that the bottle retained its seal. In the upright position, the hiss of inrushing air must be listened for. *This observation is especially important in cryonics operations, since many items are being used beyond their rated expiration dates, and often after shipping or air transport.*

- 3) Close the door and activate the oven for 15 seconds.
- 4) Open the oven and check the bottle temperature.
- 5) Repeat steps #3 and #4 above until the bottle is almost too hot to handle. *Do not try to boil the liquid inside!*
- 6) Using a paper towel remove the bottle from the oven and invert repeatedly until the crystals have all dissolved. Reheat the bottle carefully as often as necessary to maintain "hot to touch" temperature.

Bags of mannitol may be rewarmed by placing them (within their outer, protective wrap) in water that is just under boiling temperature, or with a microwave, using the following technique:

- 1) Remove outer, protective bag.
- 2) Place container in the center of the microwave oven cavity.
- 3) Heat bag for 30 seconds and evaluate for temperature.
- 4) Repeat step #3 until bag is very hot to touch.
- 5) Remove bag from oven using paper towel and repeatedly invert until crystals dissolve.

Checking For Damage

Before opening or spiking a container of IV solution, be certain to check the glass (if it is a glass container) for hairline fractures or cracks. Holding it up to a strong light and slowly rotating the bottle while carefully visually inspecting it will reveal the cracks. Because these medications will have been transported, often by air or over considerable distance, insuring that the glass is intact is of great importance. Always be sure that a vacuum is present when solutions in glass containers are first opened, or "spiked", with the solution administration set. If the bottles are spiked in the inverted position, the large bubbles will indicate that the bottle retained its seal. In the upright position, the hiss of inrushing air must be listened for. *This observation is especially important in cryonics operations since many of items used are being used beyond their rated expiration dates and often after shipping or air transport.*

Technique: Arm or Leg Vein

Since the largest of the superficial veins of the arm are in the antecubital fossa, these should be selected initially since the patient will be in a state of reduced circulation. Similarly, the long saphenous vein at the medial malleolus may be utilized first, but can be entered at any point along its course. Generally, a point between the junction of two veins is chosen for entry, since the vein is better stabilized at that point and vein puncture is more easily effected.

Technique: Arm or Leg Vein

Since the largest of the superficial veins of the arm are in the antecubital fossa, these should be selected initially, since the patient will be in a state of reduced circulation. Similarly, the long saphenous vein at the medial malleolus may be utilized first, but can be entered at any point along its course. Generally, a point between the junction of two veins is chosen for entry, since the vein is better stabilized at that point and vein puncture is more easily effected.

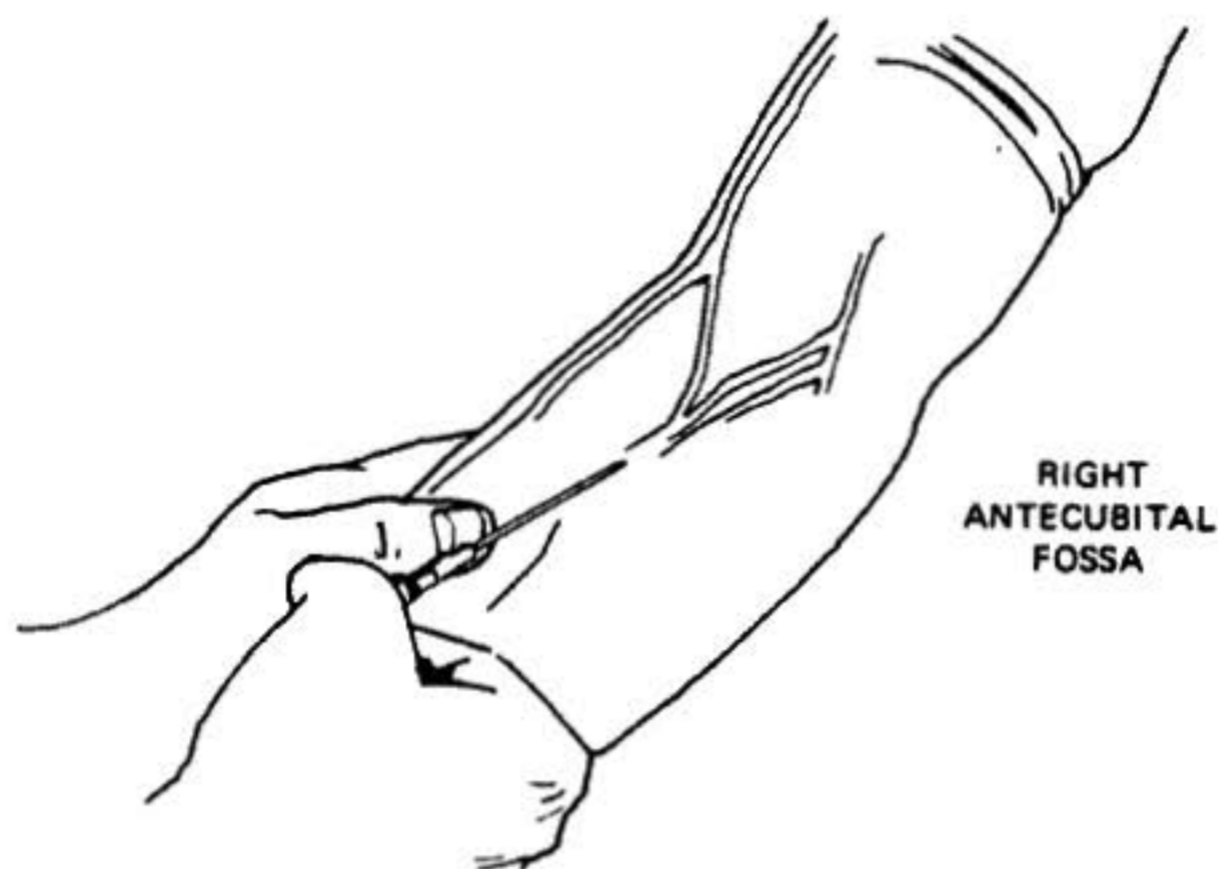


Figure 9-9: Antecubital venipuncture.

The steps for establishing a patent IV in the arm or leg veins are as follows:

- 1) Apply a tourniquet proximally (above the site selected for the stick).
- 2) Locate the vein and cleanse the overlying skin with alcohol or povidone-iodine (Betadine).
- 3) Hold the vein in place by applying pressure on the vein distal to (down the limb from) the point of entry.
- 4) Puncture the skin with the bevel of the needle upward about 0.5 to 1.0 cm from the vein; enter the vein either from the side or from above at about a 35° angle, decreasing the angle sharply upon entry of the vessel.
- 5) Check for blood return; if present, advance the catheter over the needle. Remove the tourniquet.
- 6) Withdraw and remove the needle and attach the solution administration set, which has been previously purged of air, and regulate the flow rate.
- 7) Secure the catheter in place by using 1 in. wide tape over the hub of the catheter. Tape the catheter flush with the skin--no elevation of the hub should be required to obtain an adequate flow:

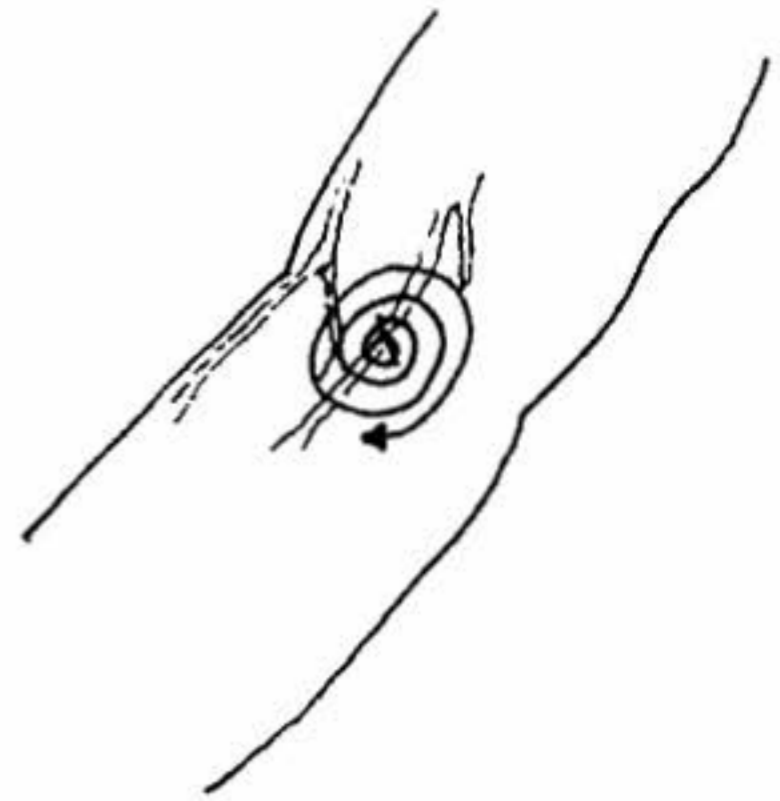


Figure 9-10: *Skin preparation technique prior to percutaneous puncture: apply betadine with a swab in a circular motion, working outward from the point where the stick is to take place.*

8) Further secure the catheter by placing a $\frac{1}{2}$ inch strip of tape--adhesive side up--under the hub of the catheter. Place one end tightly and diagonally over the hub of the catheter. Repeat with the other end, crossing over the first. This secures the catheter firmly and prevents any lateral movement. Do not cover the catheter/IV set connection or the medication addition port with tape.

9) Cover the puncture site with povidone-iodine ointment and a sterile dressing (Band-Aid).

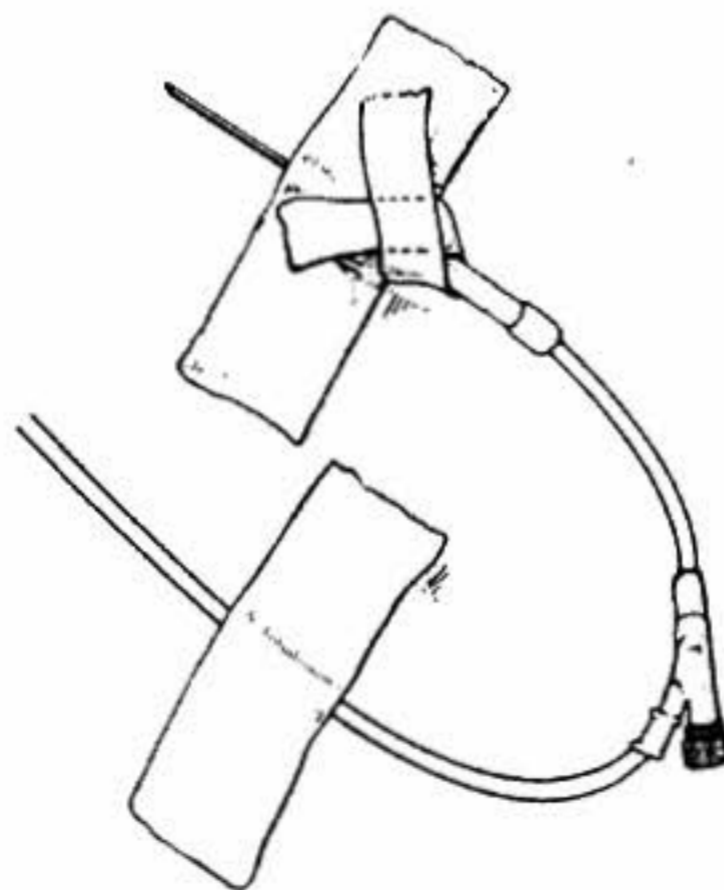


Figure 9-11: *Correct taping technique for venous cannula. Note crossover folding of securing tape, which minimizes risk of traction causing accidental removal of the cannula.*

10) Secure the solution administration set tubing to the arm in a loop (taping it independently of the catheter) to protect against accidental removal of the catheter in the event the tubing is snagged or pulled.

11) If the antecubital arm site is to be used for IV cannulation, it will be necessary to attach an armboard to prevent loss of catheter patency due to accidental flexing of the arm during transport. The armboard should be placed under the limb

THREE METHODS OF TAPING A VENIPUNCTURE SITE

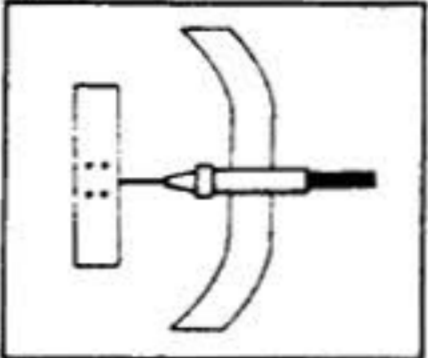
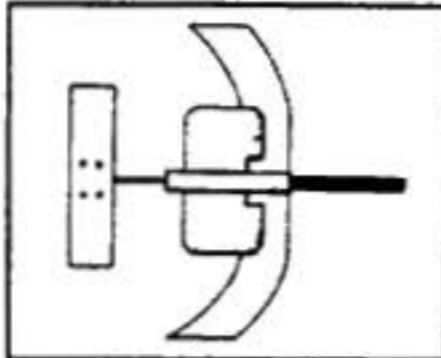
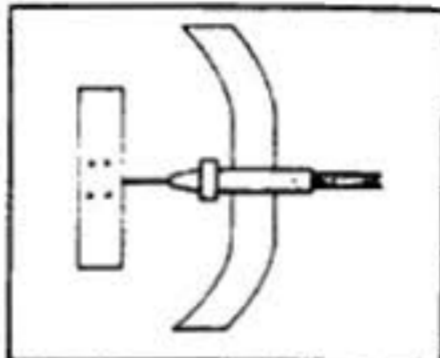
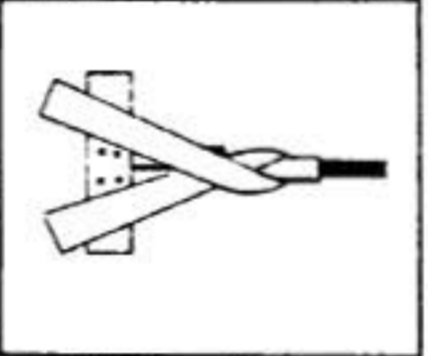
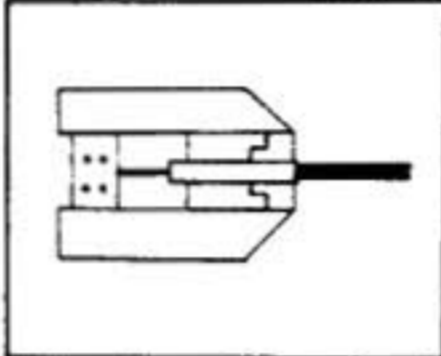
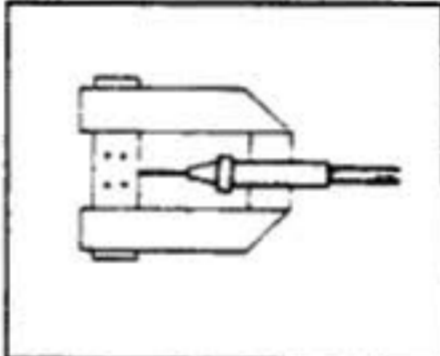
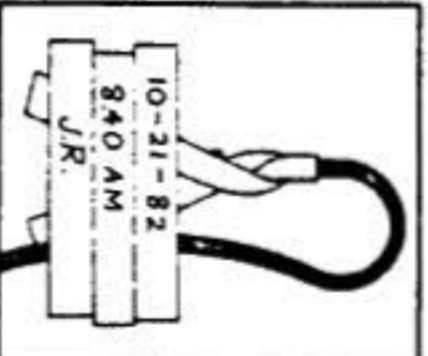
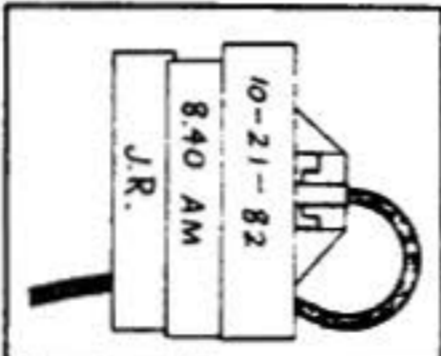
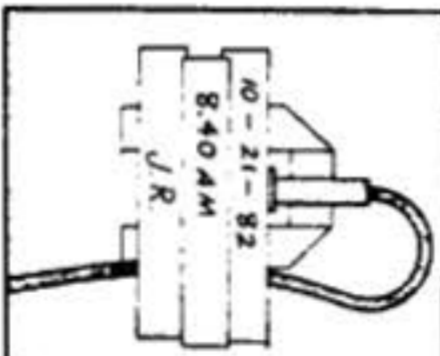

Chevron method	U method	Two-tape method
		
<p>1 Cover the venipuncture site with an adhesive strip or a 2" x 2" sterile gauze pad. Then, cut a long strip of 1/2" tape. Place one strip, sticky side up, <i>under</i> the needle, parallel to the short strip of tape.</p>	<p>1 Cover the venipuncture site with a 2" x 2" sterile gauze pad or an adhesive strip. Then, cut three strips of 1/2" tape. With the sticky side up, place one strip <i>under</i> the tubing.</p>	<p>1 Cover the venipuncture site with an adhesive strip or a 2" x 2" gauze pad. Then, place a 2" strip of 1/2" tape, sticky side up, <i>under</i> the needle.</p>
		
<p>2 Cross the end of the tape over the opposite side of the needle, so the tape sticks to the patient's skin.</p>	<p>2 Bring each side of the tape up, folding it over the wings of the needle, as shown here. Press it down, parallel to the tubing.</p>	<p>2 Fold the tape ends over and affix them to the patient's skin in a U-shape, as shown here.</p>
		
<p>3 Apply a piece of 1" tape across the two wings of the chevron. Loop the tubing and secure it with another piece of 1" tape. On the last piece of tape you apply, write the date and time of insertion and your initials.</p>	<p>3 Loop the tubing and secure it with a piece of 1" tape. On the last piece of tape you apply, write the date and time of insertion and your initials.</p>	<p>3 Place a second strip of 1/2" tape, sticky side down, over the needle hub. On the last piece of tape you apply, write the date and time of insertion and your initials. With this method, you can remove the upper strip of tape to check the insertion site while the lower strip anchors the needle.</p>
		

Figure 9-12: Taping a venipuncture site.

after the stick is complete and the patency of the IV has been determined. The armboard should be positioned such that it extends at least 6 inches above and below the elbow, and it should be lightly taped to the limb at either end.

12) Check to make sure the tourniquet has been removed.

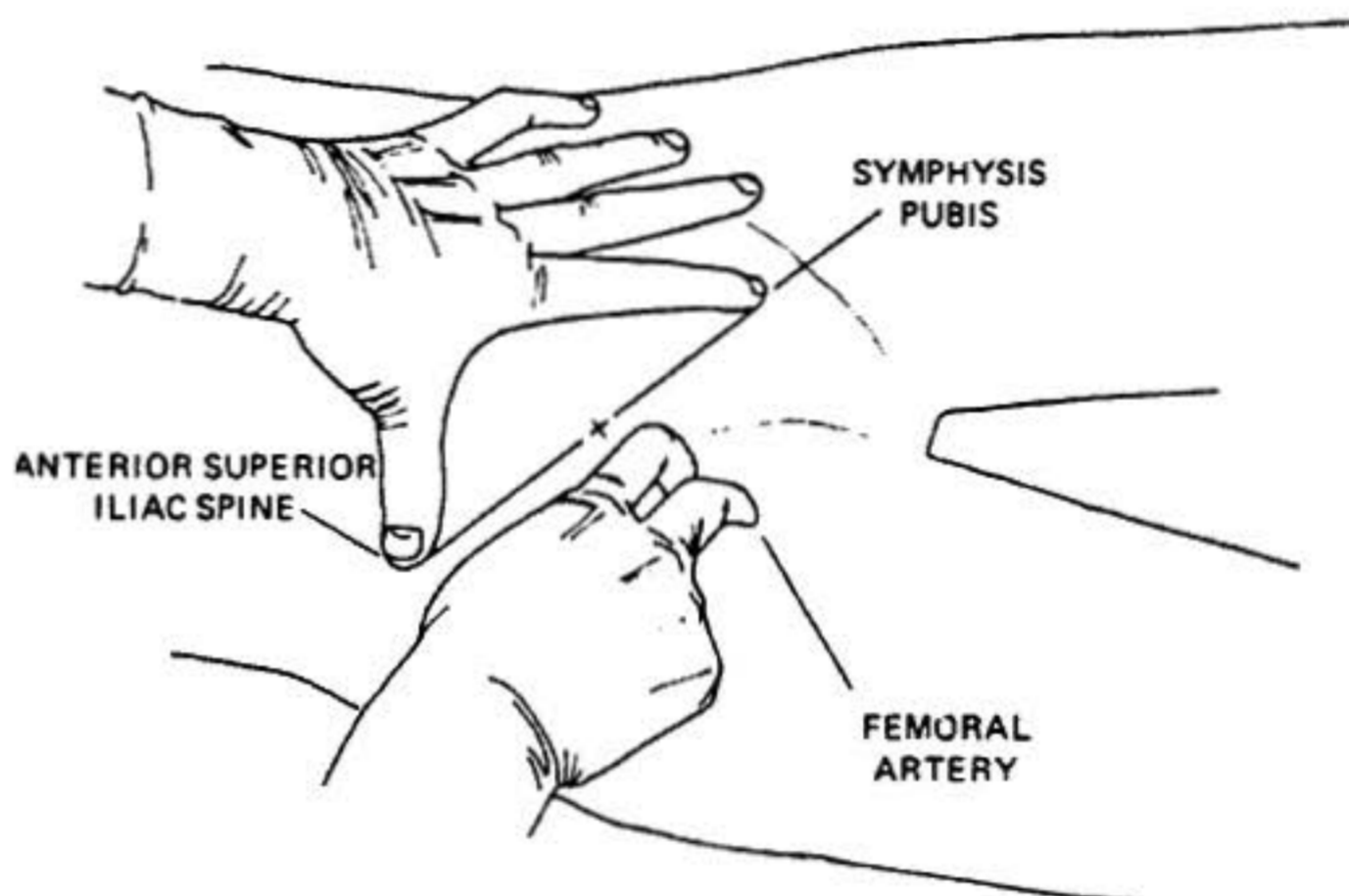
Femoral Venipuncture

If the patient is severely dehydrated or if it is otherwise not possible to stick a suitable peripheral vein, the femoral vein may be used.

Anatomy

The femoral vein lies in the femoral sheath, medial to the *femoral artery* immediately below the inguinal ligament. If a line is drawn between the *anterior superior iliac spine* and the *pubic symphysis*, the femoral artery runs directly across the midpoint; medial to that point is the femoral vein (See Figures 9-13 and 9-14 below). If the HLR is generating a sufficient pulse that the femoral artery is palpable, the femoral vein will lie immediately medial to the pulsation.

Figure 9-13: The femoral artery runs directly across the midpoint of the line drawn between the anterior superior iliac spine and the symphysis pubis.



Technique: Femoral Venipuncture

The steps for initiating IV therapy using the femoral vein are as follows:

- 1) Cleanse the overlying skin with povidone iodine.
- 2) Determine the location of the femoral artery either by its pulsations or by finding the midpoint of a line drawn between the anterior superior iliac spine and the pubic symphysis.
- 3) Make the puncture with the needle/catheter attached to a 5 cc or 10 cc syringe two fingers-breadth below the inguinal ligament, medial to the artery, directing the needle cephalically at a 45° angle to the skin (See Figure 9-15).

Figure 9-14: *The femoral vein lies medial to the femoral artery below the inguinal ligament.*

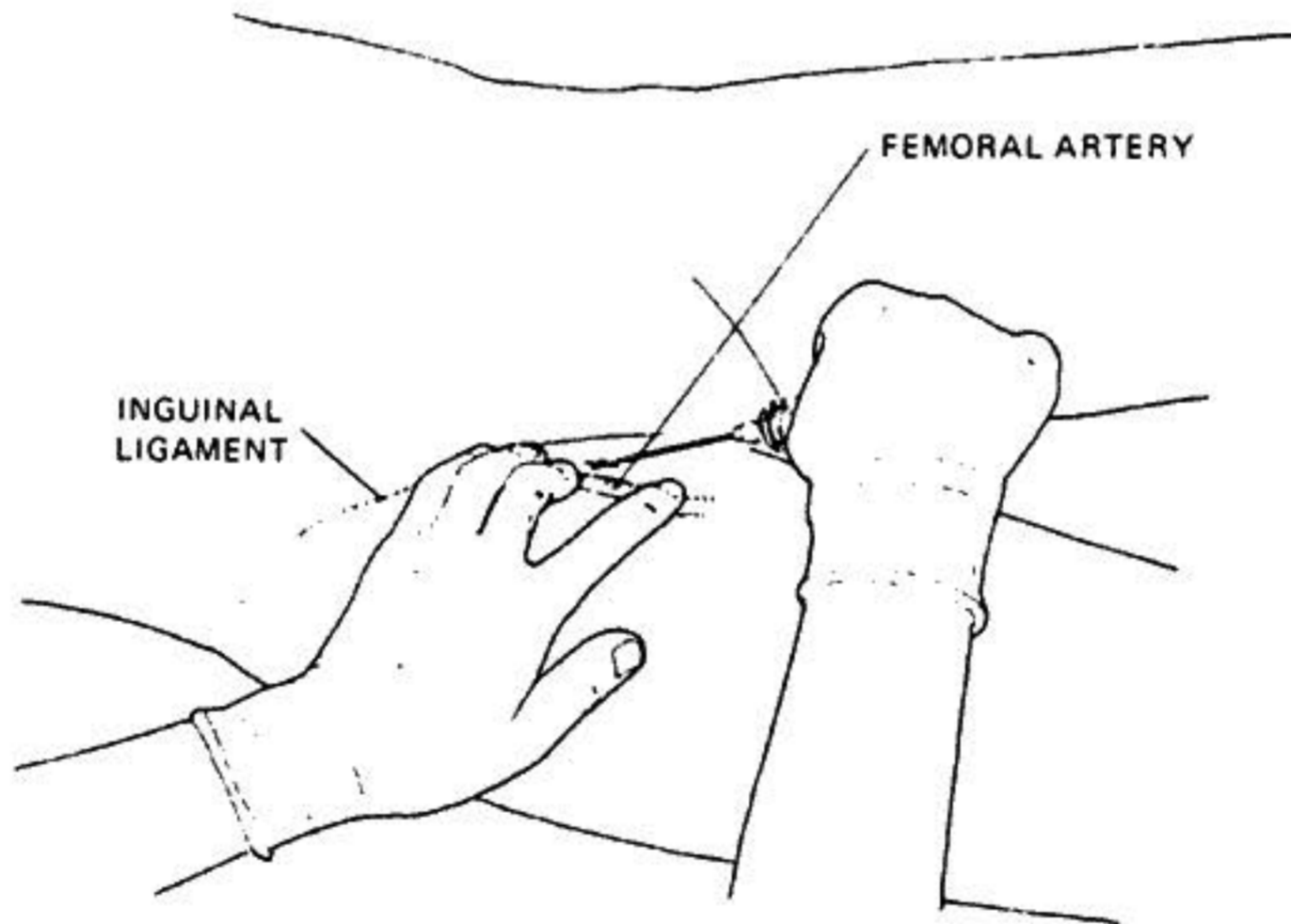
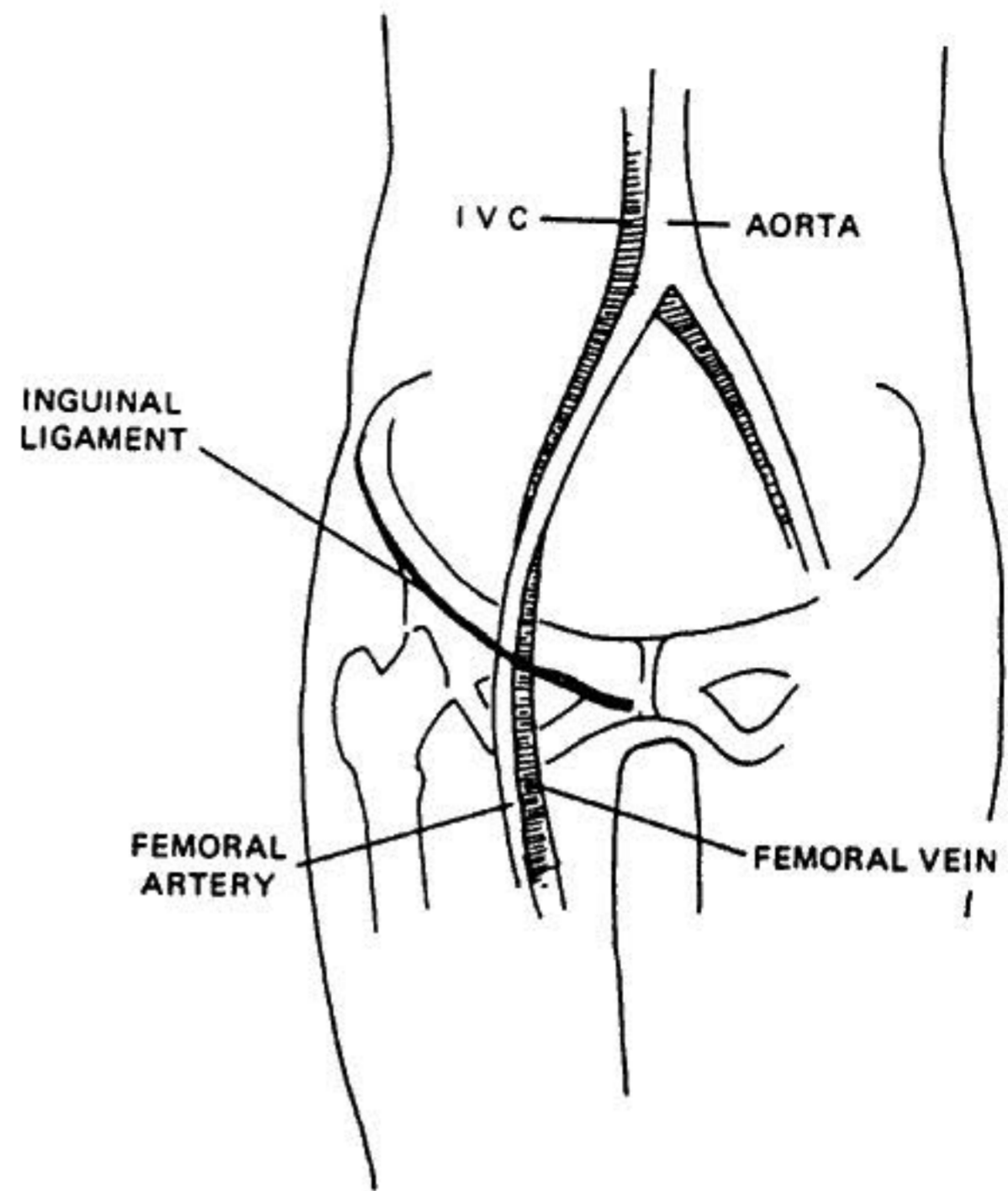


Figure 9-15: *Femoral venipuncture.*

- 4) Advance the needle slowly while maintaining suction on the syringe. When the vein is punctured, blood will appear in the syringe indicating that the lumen of the vein has been entered.
- 5) Lower the needle to a position more nearly parallel to the skin surface and advance the catheter.
- 6) Withdraw and remove the needle, attach the solution administration set which has

been previously purged of air, and regulate the flow rate.

7) Secure the catheter in place by using 1 inch wide tape over the hub of the catheter. Tape the catheter flush with the skin; no elevation of the hub should be required to obtain an adequate flow.

8) Further secure the catheter by placing a $\frac{1}{2}$ inch strip of tape--adhesive side up--under the hub of the catheter. Place one end tightly and diagonally over the hub of the catheter. Repeat with the other end, crossing over the first. This secures the catheter firmly and prevents any lateral movement. *Do not cover the catheter/IV set connection or the medication addition port with tape.*

9) Cover the puncture site with povidone-iodine ointment and a sterile dressing (Band-Aid).

10) Secure the solution administration set tubing to the groin in a loop (taping it independently of the catheter) to protect against accidental removal of the catheter in the event the tubing is snagged or pulled.

Technique: Peripheral Venous Cutdown

Venous cutdown should be used to gain vascular access only when percutaneous venous access is not possible or has proved inadequate to deliver the required volume of fluid in a timely fashion. Cutdown should not be used as a first approach to vascular access (unless assessment of the patient indicates that peripheral venous access would be difficult or impossible, i.e., severe dehydration, sclerosed peripheral vessels, etc., would result) because of the extra time involved in carrying out the operation.

Preparation For Cutdown

Gather the equipment required for the operation. The *Alcor Transport Medications Kit* (gray plastic box) contains a simple emergency cutdown kit consisting of a suture removal kit (scissors and forceps), 000 silk suture with straight cutting needle, a disposable scalpel with a #10 blade, vessel clip (parallel jaw type), and two betadine swabs. In addition to the cutdown kit, a catheter (with needle removed) and supplies for the peripheral venipuncture technique described above will be required.

Technique: Antecubital Vein Cutdown

1) Locate the *basilic vein* by applying a tourniquet above the antecubital crease (See Figure 9-16). Cutdown will be made *below* the tourniquet.

2) Cleanse the overlying skin with povidone iodine.

3) Incise the skin and expose the vein. Using the scalpel, make a 3 or 4 cm transverse skin incision over the vein just above the antecubital crease and deep enough to expose only the overlying fatty layer. Use the suture removal scissors to spread the edges of the incision and to dissect down to the vein. *Dissection should be blunt* (using only the blunt tips of the scissors in a spreading fashion) and parallel to the course of the vein, so as to lessen the risk of tearing it. Expose 2 to 3 cm of vein.

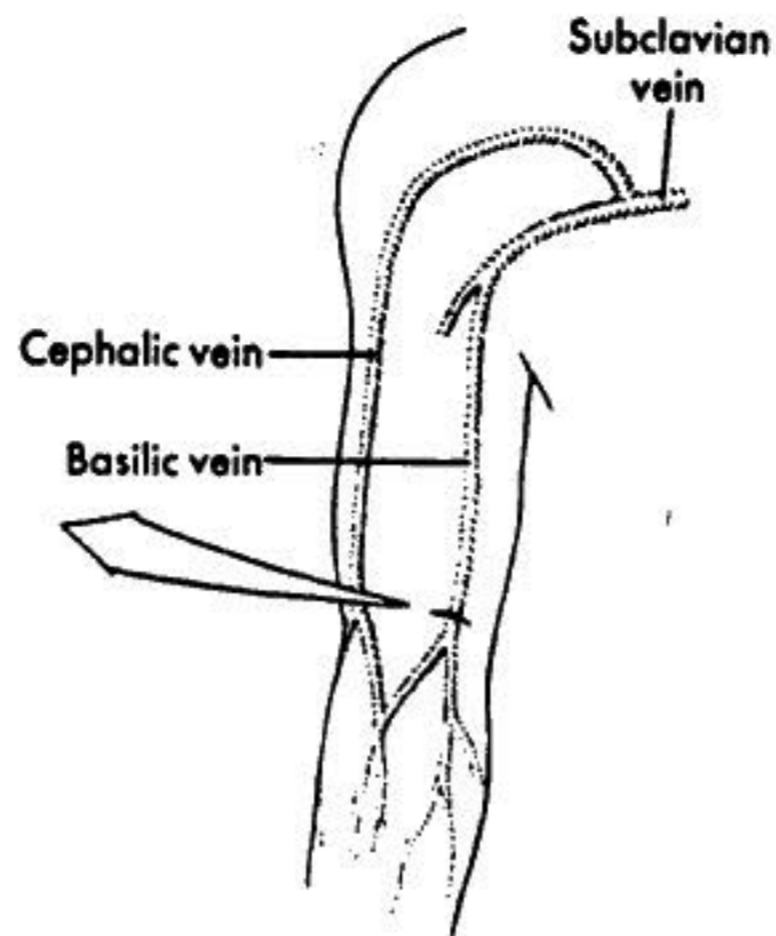
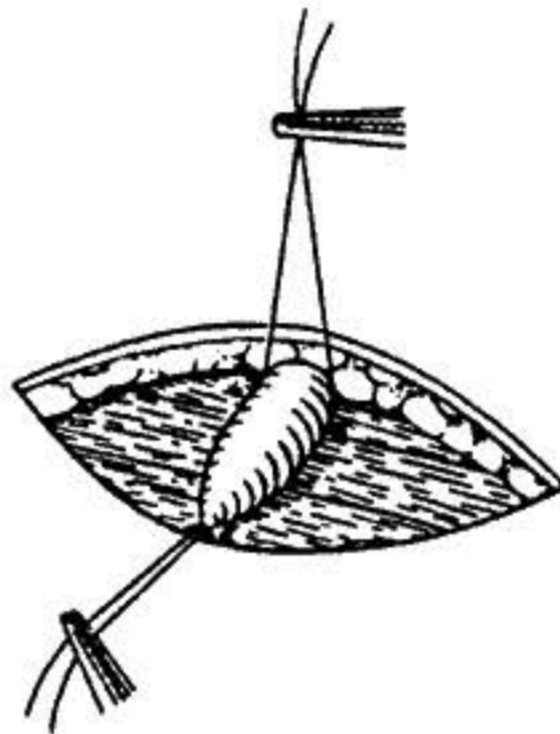


Figure 9-16: *Anatomical location of the basilic vein.*

Figure 9-17: *Isolation of the vein.*



- 4) Isolate the vein (Figure 9-17) by sliding the forceps beneath it and pulling a silk ligature back under the vein. Tie the ligature as far distally as is possible. Place a second ligature beneath the proximal end of the vein, *but do not tie it*.
- 5) Using the proximal ligature to elevate the vessel, place the spring jaw clip on the vein as close to the proximal ligature as possible. Release the tension on the proximal ligature once the clip is in place.
- 6) Pick up the vein with the forceps 1 cm or so distal from the clip and, using the scalpel, cut approximately half way through the vein (Figure 9-18).
- 7) Use the forceps to grasp the edge of the incision in the vein and "tent" it, so that the catheter may be inserted (Figure 9-19).
- 8) Release the clip and advance the catheter to the hub. Secure the catheter in the vessel by first firmly tying the proximal ligature around the catheter. Check the patency of the catheter position by gently pulling back on the plunger of the syringe

Figure 9-18: *Proper technique for incising the vein.*

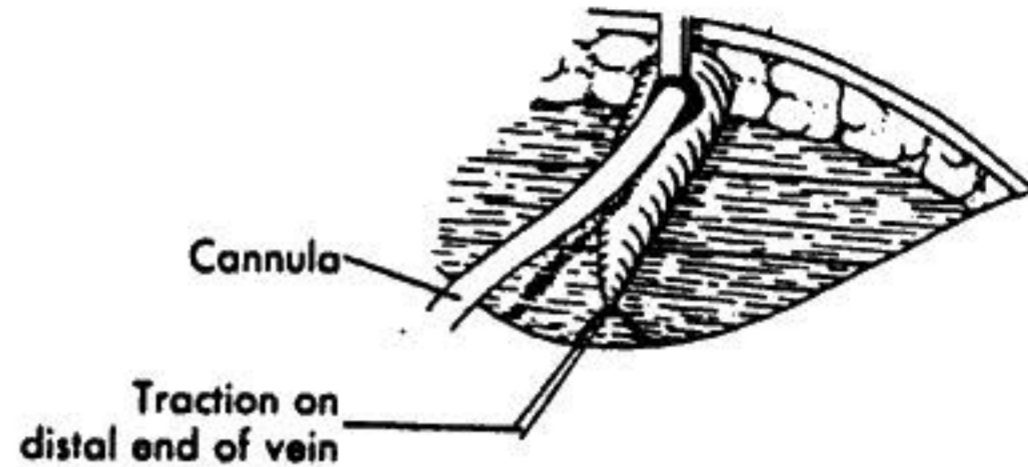
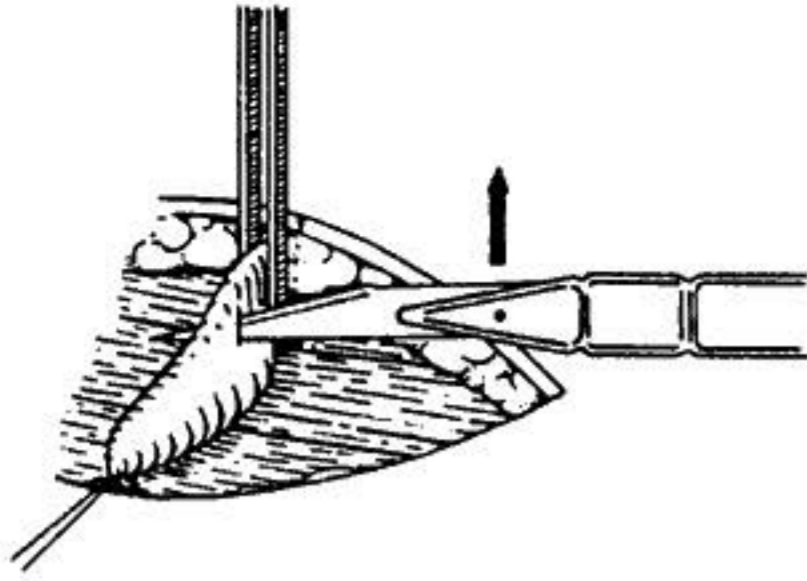


Figure 9-19: *Insertion of cannula.*

and looking for blood. (*Note: in severely dehydrated or hypovolemic patients it may not be possible to aspirate blood from the vein.*)

9) Remove the syringe and attach the solution administration set, which has been previously purged of air, and regulate the flow rate.

10) Secure the catheter in place by first taping the distal ligature over the solution administration set tubing (taking care not to occlude the tubing with too tight a knot) and then using 1 in. wide tape over the hub of the catheter. Tape the catheter flush with the skin.

11) Cover the cutdown site with a sterile dressing (gauze square and tape).

12) Secure the solution administration set tubing to the limb in a loop (taping it independently of the catheter) to protect against accidental removal of the catheter in the event the tubing is snagged or pulled.

Technique: Saphenous Vein Cutdown

1) Locate the saphenous vein, which is anterior to the medial malleolus, by applying a tourniquet above the ankle (*Figure 9-20*). Follow procedures 2 through 12 above.

Troubleshooting: When the Infusion Stops Unexpectedly

The following procedure should be used when the infusion stops:

- 1) Check for hematoma formation or infiltration.
- 2) Check fluid level in the bottle.
- 3) Check for kinking of the tubing.
- 4) Open the flow rate adjustment clamp.

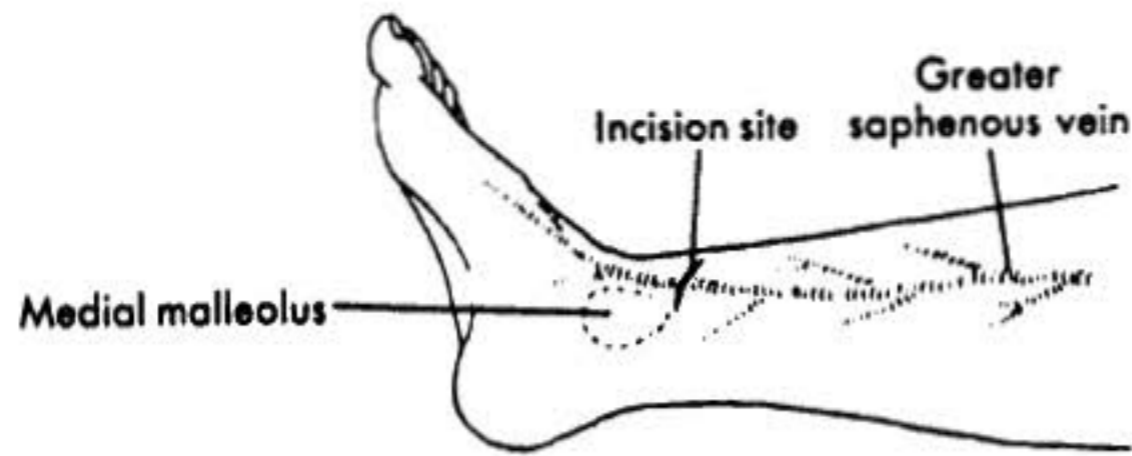


Figure 9-20: *Location of the cutdown site for the saphenous vein.*

- 5) Check air vent. (Has it been inserted, if required, and is it patent, or has it become wet with solution?)
- 6) Check the catheter for patency by kinking the administration set tubing a few inches from the catheter while pinching and releasing the tubing between the needle and the kinked tubing. Resistance, if encountered, should be treated with caution, as a clot may have plugged the catheter. If resistance is encountered, the catheter must be removed and the patient restuck.
- 7) Is the catheter in line with the vein, or up against the wall of the vein? A slight adjustment moving or very slightly pulling back on the catheter may remedy the problem.
- 8) Increase the height of the bottle to increase the pressure of the solution.
- 9) If unable to restart the infusion after these procedures have been followed, the IV must be restarted, selecting another site and resticking the patient.